



LAPAROSCOPY-PROMISING TOOL FOR IMPROVEMENT OF REPRODUCTIVE EFFICIENCY OF SMALL RUMINANTS

Dovenski Toni¹, Trojacanec Plamen¹, Petkov Vladimir¹,
Popovska-Percinic Florina¹, Kocoski Ljupce², Grizelj Juraj³

¹Faculty of Veterinary Medicine, Ss. Cyril and Methodius University, Skopje, R. Macedonia

²Faculty of Biotechnical sciences, University St. Kliment Ohridski - Bitola, R. Macedonia

³Faculty of Veterinary Medicine, University of Zagreb, R. Croatia

Received 29 March 2013; Received in revised form 18 April 2013; Accepted 23 May 2013

ABSTRACT

Assisted reproductive technologies are used to accelerate genetic gain and improve reproductive performances in farm animals, including small ruminants. This technologies include estrous synchronization, artificial insemination (AI) using fresh, frozen or sexed semen, embryo transfer (ET) using *in vivo* or *in vitro* produced embryos, and more advanced - cloning and production of transgenic animals. Diagnostic procedures, such as ultrasonography and laparoscopy, have been used as additional tools for monitoring the ovarian response to superovulatory treatment in donor animals as well as for AI and collection and transfer of embryos.

The use of laparoscopy for assisted reproduction techniques in Macedonia commenced in the early 90's, with the acquisition of a set of „Karl Storz” equipment. After the adoption of the required routine, our group has completed several scientific projects where laparoscopy was used for intrauterine inseminations as well as for recovery and transfer of embryos in both sheep and goats. In the following period our group endeavored into introduction of laparoscopic insemination in the routine farm practice. Ovine intrauterine/intracornual insemination by frozen-thawed semen resulted with pregnancy rates of 45% and 60%, when AI was performed out of season and during the breeding season, respectively. In goats, this percentage occasionally peaked at 85%.

The aim of this article is to review the status of implementation of laparoscopy in Assisted Reproduction Technologies (ART) of small ruminants and to present our experience in this field.

Key words: laparoscopy, reproduction, artificial insemination, embryo transfer, small ruminants

INTRODUCTION

The assisted reproduction technologies (ART), used in animal breeding, includes various methods for improvement of the genetic value of the production animals as well as for promotion of superior genotypes. ART represent a combination of scientific knowledge in reproductive physiology, endocrinology, cellular and molecular biology as well as genomic techniques. (1). In the last 30 years this technology experienced a dynamic development, especially in the dairy cows Embryo transfer indus-

try (review: 6, 9). Ultrasonography and laparoscopy are the most practical tools for monitoring of ovarian and uterine dynamics during different biotechnical procedures. Ultrasound diagnostics is more frequently used in large ruminants, by simply adding an ultrasound probe during the routine rectal examination. However in small ruminants laparoscopy seems to be more acceptable and practical instrument for this purpose.

Laparoscopy, (Gr: *Laparo*-abdomen, *scopein*-to examine) represents a technique for examination of the abdominal cavity and its contents. It requires insertion of a cannula/trocar through the abdominal wall, distension of the abdominal cavity with sterile air or CO₂ (pneumoperitoneum), and visual examination of the abdomen's contents with an illuminated telescope.

Corresponding author: Prof. Toni Dovenski, PhD

E-mail address: dovenski@fvm.ukim.edu.mk

Present address: Department of reproduction, Faculty of Veterinary medicine-Skopje, “Ss. Cyril and Methodius” University, Lazar Pop- Trajkov 5-7, 1000 Skopje, R. Macedonia
tel: +389 2 3240 767; fax: +389 2 3114 619

Roberts (1968) (25) first reported endoscopic/laparoscopic examination of reproductive organs in sheep. Endoscopy was initially used for “direct ob-

servation of the ovaries (Fig. 1.) and uterus (Fig. 2.) of the ewe by means of an illuminated endoscope, inserted through an abdominal cannula”.

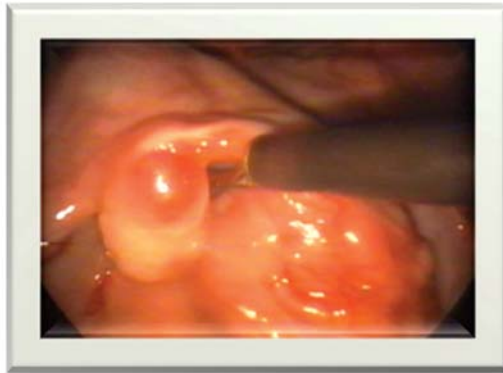

Figure 1. Preovulatory follicle on sheep ovary - laparoscopic view

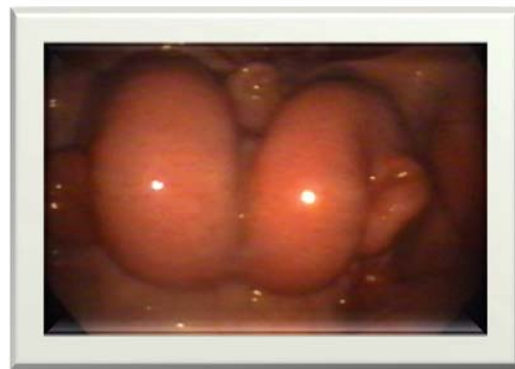

Figure 2. Laparoscopic view of a sheep uterus in estrus

With the introduction of video cameras and other ancillary instruments (Fig. 3.) laparoscopy rapidly advanced from being just a diagnostic pro-

cedure to one used in numerous surgical procedures in all surgical disciplines for a variety of indications (30).

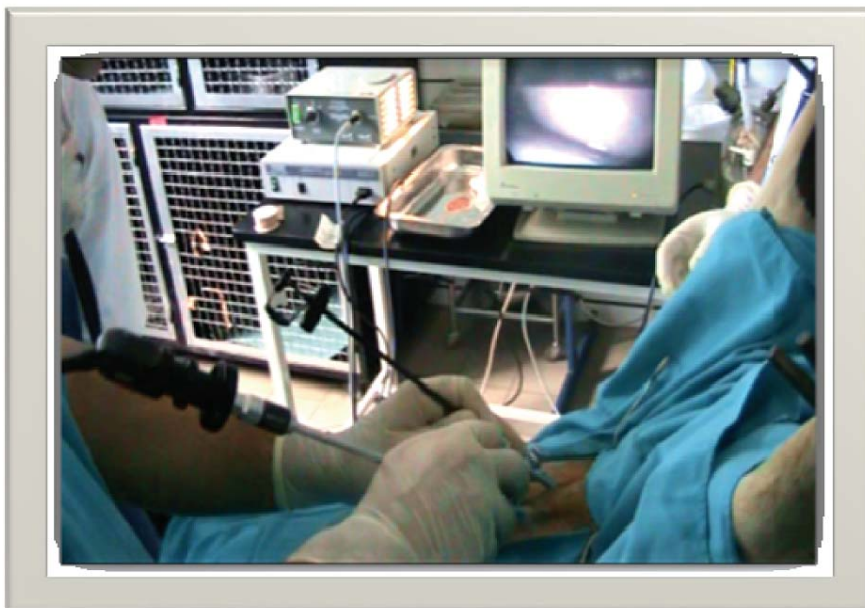

Figure 3. Standard setup of laparoscopic equipment for insemination of sheep

Moreover, the development of assisted reproductive methods brought laparoscopy into the focus as a technique for study of ovulation, follicles and corpora lutea development, as well as for pregnancy diagnosis. Salamon and Maxwell (26) recognized the laparoscopic intrauterine insemination of sheep as the most effective method used to improve the fertility.

Using laparoscopy, the “cervical barrier” problem has been overcome and satisfactory fertility rate has been achieved by significant reduction in the number of spermatozoa per insemination (from 200-300 to 1-10 millions, or less for sex-sorted semen). Pregnancy rate is commonly over 75% and 50% for goats and sheep respectively (26).

Laparoscopic technique was introduced in MOET programs by McKelvey et al. (19). Primary purpose was to reduce adhesions of the reproductive system after surgical embryo recovery. Laparoscopy enables repeated flushing of sheep and goats uterus and satisfactory embryos recovery rate. Also, fresh or frozen-thawed embryos are transferred to the utera or oviducts of recipients by laparoscopy, achieving high pregnancy rates. Laparoscopy is also used for oocytes aspiration (Laparoscopy Ovum Pick Up - LOPU) in small ruminants (13).

The aim of this article was to bring to light the current state (advances and pitfalls) of implementation of laparoscopy in small ruminants, as a valuable tool for assisted reproductive technologies.

Laparoscopic Artificial Insemination (LAI)

The last few decades have noticeably changed the management of sheep breeding, through improved nutrition and veterinary assistance. Artificial insemination is the most commonly applied reproductive technology in selection programs (15). Satisfactory results of transcervical insemination have not been achieved yet, especially out of the breeding season and using deep frozen-thawed ram semen. Fertilization failure is equally frequent in ewes bred naturally or artificially inseminated, and appears to be due to faulty transport of spermatozoa through the cervix (7). This problem can be overcome by intra-uterine deposition of semen through surgical procedure in superovulated ewes or by laparoscopic insemination (16). Killen and Caffery (17) have developed a laparoscopic artificial insemination technique (LAI). Intra-uterine insemination is especially effective in overcoming the fertilization

failure of superovulated donors, exhibiting high ovulation rates. In sheep, intra uterine laparoscopic insemination should be carried out in the middle of the estrous period (31). However, some authors (16) reported that when fertile rams are available, natural mating should be used in the superovulation program, and sheep should be mated every 6 h during standing estrus.

Laparoscopic Artificial Insemination

Ewes are fasted and restricted access to water for 16 hours before, and injected with local anesthetic 15 minutes before the procedure is performed. The ewe is then placed in a laparoscopy cradle. The abdominal region is surgically prepared by shearing the wool and disinfecting the skin. Using the cradle, the ewe is positioned in a supine head-down (Trendelenburg) position to an approximate angle of 30° (Fig 4).

The trocars and cannulae for introducing laparoscope and insemination pipette are inserted 7 – 10 cm ventral to the udder and 5 – 10 cm on each side of the midline (*linea alba*) (Fig 5). Usually, a scalpel blade is used to make a small skin incision in order to facilitate trocar penetration. The 7 mm trocar and cannula that is connected with the CO₂ is first introduced and the abdomen is slightly inflated to reduce the chance of injury to organs. Insertions of the first trocar and cannula should be well controlled and the sharp trocar is withdrawn as soon as the abdominal wall has been penetrated. The blunt cannula is pushed well into the abdomen, while the second trocar and cannula are inserted after inflation with CO₂. Endoscope and AI instrument go through the cannulae and the uterus is located and fixed just ventral to the urinary bladder. Semen is deposited in each uterine horn approximately halfway between the uterine bifurcation and the utero-tubal junction (Fig. 6).

A light stab action of the aspic and the turn of the plunger deposit about 0,1 ml of diluted or frozen thawed semen into the lumen of each uterine horn (total 0,2 ml). Instruments are withdrawn and put into disinfectants between each animal. An antibiotic spray is applied to the wounds. Occasionally bleeding may be caused by perforation of a subcutaneous blood vessel or uterine horns wall (Fig. 7). The wound can be sutured or an artery clamp can be applied. Fatalities are possible, when the abdominal aorta is pierced with an uncontrolled and brutal in-

section of the first trocar. It is possible to pierce a full rumen as well as a full bladder. Operators should be well trained.

Similar procedure, with slight variation, has been described in goat (28). Before laparoscopic AI, animals are deprived of feed for 2 d, and of water for 1 d. Emptiness of the digestive tract and bladder facilitates fast and easy operation and decreases the pressure exerted by the abdominal organs on the diaphragm while the animals are in a supine head-down position. Laparoscopic insemination, in details is described by Vallet et al. (29). Briefly, the animals should be tilted into a head-down position at an angle of at least 30°. Approximately 8 cm cranial to the udder and 8 cm to the left and right of the midline, the skin should be nicked with the tip of a scalpel blade and, with the aid of a trocar, two 5-mm cannulas have to be inserted through the abdominal wall. The abdominal cavity is insufflated with a moderate amount of sterile air to aid visibility. A laparoscopic telescope and an insemination instrument are introduced through the cannulas. The uterine horns should be punctured with the fine tip of the insemination pipette near the middle of the great curvature, in the least vascularized area, to deposit the semen in the uterine lumen. The sperm could be distributed to one (if preovulatory follicle is found on the ipsilateral ovary) or both uterine horns.

Dovenski et al. (8) have reported high percentage of fertilization in goats after the insemination by laparoscopic intrauterine and transcervical techniques. The lambing rate as well as the fertility rate had higher tendency (80.95% vs. 67.48%) and

(182.35% vs. 176.98%) after intrauterine than after cervical insemination, respectively.

Petkov and Dovenski (21) compared the cervical vs. intrauterine unicornal or bicornal laparoscopic insemination of sheep by frozen-thawed semen out of breeding season. They reported higher fertility rate for I/U insemination (54% and 52% for uni/bicornal A.I., respectively) than cervical insemination 38%.

More recently Dovenski et al. (10) reported similar results after insemination of Ovchepolean Pramenka sheep by deep frozen/thawed ram semen, based on ultrasound pregnancy diagnosis on day 60. Fertility rate was significantly higher ($p < 0.05$) in sheep inseminated laparoscopically (54.54%) comparing to the intracervical insemination (42.86%). Laparoscopic insemination in superovulatory estrus induced by eCG (1200 IU) and FSH (200 mg of NIH-FSH-P1 in 6 decreasing doses) have shown very high fertility rate in both groups 83.33% and 71.43% respectively.

Investigating ovarian macrostructures during the periovulatory periods some authors reported (22) that for precise estimation the use of both methods: ultrasonography and laparoscopy is necessary. Transrectal ultrasonography enables precise estimation of the ovarian size and diameter of follicles and CL's. However, ultrasound examination is less accurate for determination of number of ovarian structures then laparoscopy: $67 \pm 11\%$, $50 \pm 12\%$, $55 \pm 12\%$, $60 \pm 10\%$ for growing follicles, ovulation, CL and Cysts, respectively.

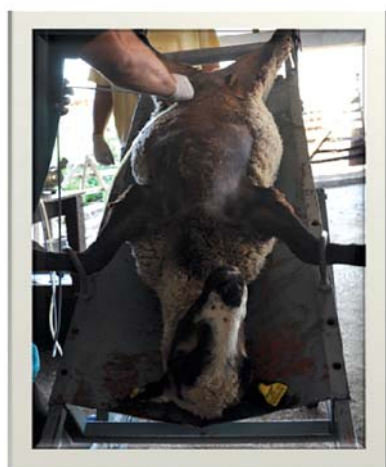

Figure 4. Positioning of the animal in a supine head-down (Trendelenburg) position for laparoscopy

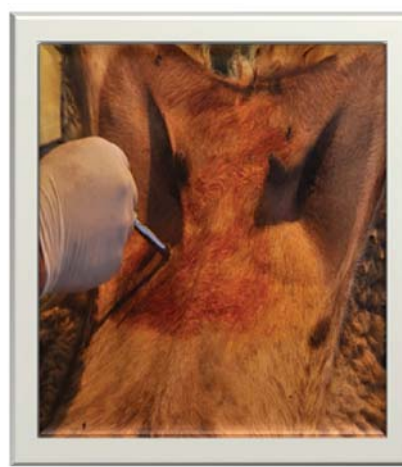

Figure 5. Typical insertion point of a trocar for laparoscopy

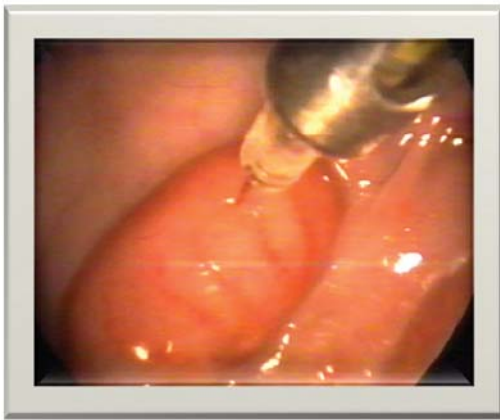


Figure 6. Correct laparoscopic semen deposition at the least vascular location of the ewe's uterus

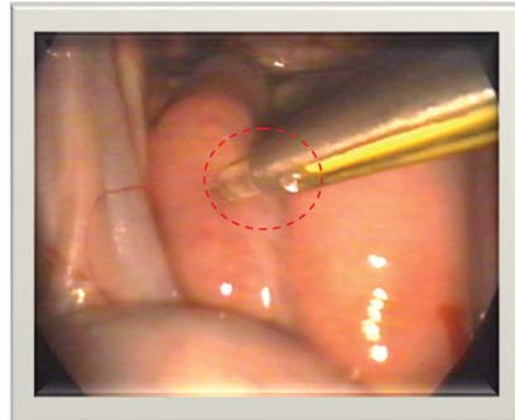


Figure 7. Incorrect insemination; wrong angle of needle insertion (left horn) and bleeding of right uterine horn

Recovery and transfer of embryos and oocytes

Most MOET programs in sheep and goat consist of a 14 to 17 day progesterone exposure, with multiple FSH injections beginning 2 days before the removal of the progesterone releasing device (4, 14). Flushing of the uterus for recovering 6-7 days old embryos (morula or blastocyst stage mostly) usually is done surgically. The occurrence of adhesions after this procedure may reduce the number of flushings obtainable from one donor (20). Laparoscopic techniques for embryo recovery in sheep have been introduced by McKelvey et al. (19), in purpose to to reduce the extent of surgical

intrusion. Laparoscopic embryo collection is less invasive and allows up to 7 collections per one animal (3).

Procedure for laparoscopic embryo recovery is similar to the LAI, with using of three instruments: endoscope, forceps for holding uterine horn and a three-way balloon catheter for flushing of embryos (24). The major problems related to repeated superovulation and frequent oocyte or embryo collection procedures are adhesions caused by protrusions of the endometrium at the puncture site. However, similar problem have been recorded during embryo recovery by laparotomy (Fig. 8. and Fig. 9.).

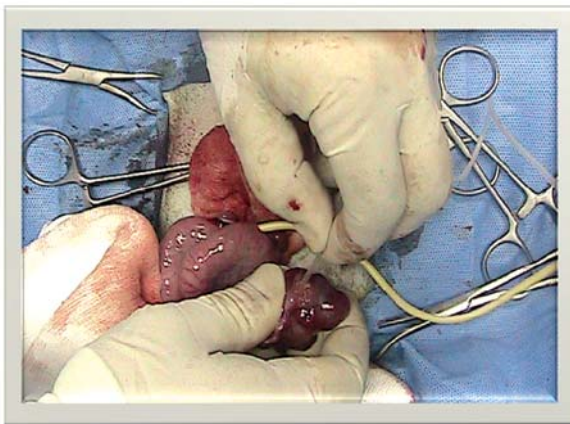

Figure 8. Flushing of embryos in ewes – surgical method

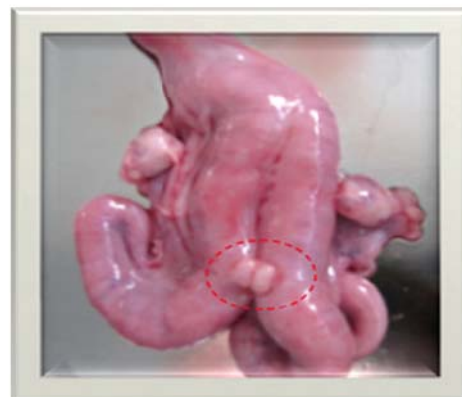

Figure 9. Adverse effect of surgical embryo collection - Protrusion of the endometrial lining through the wound at the site of catheter insertion.

Laparoscopic transfer of embryos in uterine horn (27) or tubal transfer (5) resulted with higher pregnancy rates than the surgical transfer. They have concluded that laparoscopic transfer is a safe, minimally invasive surgical procedure and it should be recommended for transfer of embryos in small ruminants.

Successful transcervical embryo transfers in small ruminants also have been reported, but only limited studies have been carried out on this matter (11). The same authors also reported that laparoscopic oocyte aspiration technique is relatively simple and effective, as well as being less traumatic than normal embryo recovery procedures (12).

Considering the possible negative consequences of laparoscopy, there is evidence that twofold and threefold applications of laparoscopy for diagnostic purposes or A.I. are not related with severe stress symptoms or any dramatic increase of the plasma cortisol level (23).

Armstrong and Evans (2), concluded that intra-uterine insemination using the technique of laparoscopy is a relatively simple and convenient means of achieving high fertilization rates in superovulated ewes when frozen semen is used. Embryo recovery was not impaired in ewes inseminated by this technique, and with proper care to avoid damage to mammary blood vessels, or deposition of semen within the uterine stroma, there were no detrimental consequences to the ewes.

In conclusion, application of laparoscopy in small ruminant assisted reproduction would be economically reasonable in MOET programs (I/U insemination as well as for uterine flushing and embryo transfer), especially for insemination of genetically valuable animals with high-quality imported ram and goats semen. This technique has factual limitations for wider application in the expensive equipment, and the special staff training.

REFERENCES

- Alexander, B., Mastromonaco, G., King, W.A. (2010). Recent Advances in Reproductive Biotechnologies in Sheep and Goat. *J Veterinar Sci Technol* 1:101. doi:10.4172/2157-7579.1000101
- Armstrong, D. T., Evans, G. (1984). Intrauterine insemination enhances fertility of frozen semen in superovulated ewes. *Journals of Reproduction & Fertility* 71: 89-94.
- Baril, G., Pournard, J., Freitas, V., Leboeuf, B., Saumande, J. (1996). A new method for controlling the precise time of occurrence of the pre-ovulatory gonadotropin surge in superovulated goats. *Theriogenology* 45: 697-706.
- Barry, D.M., Van Niekerk, C.H., Rust, J., van der Walt, T. (1990). Cervical embryo collection in sheep after ripening of the cervix with prostaglandin E2 and estradiol. *Theriogenology* 33:190.
- Besenfelder, U., Zinovieva, N., Dietrich, E., Sohnrey, B., Holtz, W. & Brem, G. (1994). Tubal transfer of goat embryos using endoscopy. *Vet. Rec.* 135, 480-481.
- Betteridge KJ. (2003). A history of farm animal embryo transfer and some associated techniques. *Anim Reprod Sci.* 15;79(3-4):203-244.
- Boland, M.P., Crosby, T.F., Gordon, I. (1983). Factors influencing the superovulatory response in sheep. *Theriogenology* 19:114.
- Dovenski, T., Popovski, K., Petkov, V., Mickovski, G., Kocoski, Lj., Trojancanec, P., Stojanovski, B. (1997). Comparison of intrauterine and cervical insemination in goats with deep-frozen semen. *Croatian veterinary congress, Proceedings* pp. 279-285, Cavtat, Croatia
- Dovenski, T., Trojancanec, P., Petkov, V., Popovska-Percinic, F., Kocoski, Lj. (2011). Using of ultrasound guided Ovum Pick-Up (OPU) in Bovine Embryo Industry as an alternative to superovulatory treatment. *Proceedings of the 2nd Conference of Balkan Network for Animal Reproduction Biotechnology*, pp. 36-39, Sofia, Bulgaria
- Dovenski, T., Trojancanec, P., Petkov, V., Popovska-Percinic, F., Dovenska, M., Atanasov, B., Ilievska, K., Mickov, Lj., Nikolovski, M. (2012). Ovine Laparoscopic Intrauterine Artificial Insemination by Deep-Frozen/Thawed Ram Semen from Ovchepolean Pramenka Breed. *Abstracts from the SEE.ERA.net Project Indi. Sheep.Tradi.Cheese.*, pp. 12-13, Thessaloniki, Greece
- Flores-Foxworth, G., McBride, B.M., Kraemer, D.C., Nuti, L.C. (1992). A comparison between laparoscopic and transcervical embryo collection and transfer in goats. *Theriogenology* 37:213.

12. Flores-Foxworth, G., Coonrod, S.A., Moreno, J.F., Byrd, S.R., Kraemer, D.C., Westhusin, M. (1995). Interspecific transfer of IVM IVF-derived Red sheep (*Ovis orientalis gmelini*) embryos to domestic sheep (*Ovis aries*). *Theriogenology* 44:681-690.
13. Gibbons, A., Pereyra Bonnet, F., Cueto, M.I., Catala, M., Salamone, D.F., Gonzalez-Bulnes, A. (2007). Procedure for maximizing oocyte harvest for in vitro embryo production in small ruminants. *Reprod Domest Anim* 42(4):423-426.
14. Gonzalez-Bulnes, A., Baird, D.T., Campbell, B.K., Cocero, M.J., Garcia-Garcia, R.M., (2004). Multiple factors affecting the efficiency of multiple ovulation and embryo transfer in sheep and goats. *Reprod Fertil Dev* 16: 421-435.
15. Grazul-Bilska, A. T. (2004). Assisted reproductive technology in sheep. *Western Dakota Sheep and Beef Day Report No. 45*, pp. 57-67.
16. Ishwar, A.K., Memon, M.A. (1996). Embryo transfer in sheep and goats: a review. *Small Ruminant Res* 19:35-43.
17. Killen, I. D. Caffery, G. J. (1982). Uterine insemination of ewes with the aid of a laparoscope. *Aust Vet J* 59:95.
18. Paramio, M.T. (2010). In vivo and in vitro embryo production in goats. *Small Ruminant Research* 89, 2, 144-148.
19. McKelvey, W.A.C., J. Robinson, J., Aitken, R.P., Robertson, I.S. (1986). Repeated recoveries of embryos from ewes by laparoscopy. *Theriogenology* 25:855-865.
20. Nellenschulte, E, Nieman, H. (1992). Collection and transfer of ovine embryos by laparoscopy. *Anim Reprod Sci* 27:293-304.
21. Petkov, V., Dovenski, T. (2007). Laparoscopic technique of Artificial Insemination with frozen semen in small ruminants. 9. Symposium on Veterinary Clinical Pathology and Therapy "Clinica Veterinaria" Palic, Serbia.
22. Ralchev, I., Lalev, I., Dovenski, T., Trojancanec, P., Petkov, V. (1994). Investigation on the possibilities of laparoscopy and ultrasound for morphological diagnosis of ovarian structures in sheep during preovulatory period. *Proceedings of the Joint Scientific Meeting on Reproduction, Veterinary Medicine and Animal Husbandry*, 90-95, Sofia, Bulgaria
23. Ralchev, I., Vlahov, K., Kanchev, L., Lalev, I., Sapundjiev, E., Popovski, K., Dovenski, T., Trojancanec, P., Kocoski, Lj. (1996). Blood cortisol levels in ewes subjected to laparoscopy during the periovulatory period. *Macedonian Journal of Reproduction* 2,2, 173-176.
24. Ralchev, I., Maslev, Tz., Todorov, M., Hristova, Tz. (2005). Technical aspects of accepting the embryos of sheep-donors using median laparotomy and laparoscopy. *Biotechnology in Animal Husbandry* 21, (5-6): 89-92.
25. Roberts, E.M., (1968). Endoscopy of the reproductive tract of the ewe. *Proc. Austr. Soc. Anim. Prod.* 7, 192.
26. Salamon, S., Maxwell, W.M.C. (2000). Storage of ram semen. *Animal Reproduction Science* 62, 77-111.
27. Stefani, J.S., Pahla, M.D.C., Christmann, L., Rosa, J.M., Silveira, M.C., Rodrigues, J.L. (1990). Laparoscopic versus surgical transfer of ovine embryos. *Theriogenology* 33:330.
28. Sohnrey, B. Holtz, W. (2005). Technical Note: Transcervical deep cornual insemination of goats. *J Anim Sci* 83:1543-1548.
29. Vallet, J. C., Baril, G., Leboeuf, B., Perrin, J. (1992). Insemination artificielle intra-utérine sous contrôle laparoscopique chez les petits ruminants domestiques. *Ann. Zootech* 41:305-309.
30. Vilos, G.A., Ternamian, A., Dempster, J., Laberge, P.Y. (2007). Laparoscopic entry: a review of techniques, technologies, and complications. *J Obstet Gynaecol Can* 29(5):433-447.
31. Walker, S.K., Smith, D.H., Seamark, R.F. (1986). Timing of multiple ovulation in the ewe after treatment with FSH or PMSG with or without GnRH. *J Reprod Fertil* 77:135-142.